

**DATE PRESENTING CLINICAL SIGNS**

2.27.22 Non resolving hematuria. Possible abdominal mass/abnormal GI pattern on radiograph. Changes near bladder. History of spay/mammary mass at same time Nov 2022.

PATIENT

Chloe Fischer

Current Medications: Clavamox 62.5mg Started 12/5 for 14 days.
 Lab Results: See attached. USG 1.024

SPECIES

Canine

Radiographs: See attached.
 Date of Previous IntraPet Ultrasound: No previous.
 Sedation: Not required to complete full diagnostic ultrasound.
 Stat Report: Not requested.
 Imaging Performed By: Stephanie Warga RDCS, RVT.

BREED

Yorkie Mix

ULTRASONOGRAPHIC EXAMINATION OF THE ABDOMEN**SEX**

Spayed Female

Urinary System

The urinary bladder is empty. The wall is of approximately thickness for the level or repletion. No cystic calculi are observed. The region of the trigone is normal. (See also "Other" category).

AGE

11/30/2007

The left kidney is normal size (3.84 cm in length) with a slightly irregular shape. There is mild to moderate loss of corticomedullary distinction. Several hyperechoic shadowing diverticular foci are observed. A 1.07 cm cortical cyst is observed at the medial aspect. The cyst causes mild capsular expansion. There is no evidence of pyelectasia, infarcts or hydronephrosis. Renal vasculature is normal.

WEIGHT

9.1 lbs

The right kidney is normal size (3.71 cm in length) with a normal shape, smooth peripheral margins, and normal internal architecture. There is moderate loss of corticomedullary distinction. Several hyperechoic shadowing diverticular foci are observed. There is no evidence of pyelectasia, infarcts or hydronephrosis. Renal vasculature is normal.

INTERPRETED BY

Andrea Nicastro, DMV,
 Diplomate DACVIM
 (Small Animal
 Internal Medicine)

Adrenal Glands

The left adrenal gland is enlarged (0.66 cm at cranial pole) (0.71 cm at caudal pole) (1.93 cm in length) with a slightly irregular shape. The parenchyma is heterogenous with some loss of glandular detail. The phrenicoabdominal vein and surrounding vasculature are normal.

HOSPITAL NAME

Animal Care Center

The right adrenal gland is enlarged (0.65 cm at cranial pole) (0.77 cm at caudal pole) (1.76 cm in length) with a normal shape and homogenous parenchyma. The glandular echogenicity and detail are unremarkable. Capsule, cortex, and medullary definition are normal. The phrenicoabdominal vein and surrounding vasculature are normal.

REFERRING VET

Dr. Anderson

Spleen

The spleen is normal in size (0.56 cm in width at the level of the hilus) with a normal capsular contour. There is appropriate echogenicity and echotexture. No focal lesions are observed. Splenic vasculature is normal.

INVOICE

11946

Liver

The liver is subjectively prominent in size with swollen curvilinear peripheral contours. The parenchyma is isoechoic relative to the spleen and exhibits mild heterogeneity. No distinct focal lesions are observed. Hepatic vasculature and biliary tracts are of normal volume with no evidence of congestion.

The gall bladder lumen is moderately distended. The wall is thin and smooth. A small to moderate amount of aggregated, mostly gravity dependent debris/sludge is observed within the lumen. The cystic and common bile ducts are normal/not seen.

Gastrointestinal

The stomach and intestine are free of stasis and exhibit normal peristaltic activity. The gastric lumen is not distended. The gastric wall and pylorus are normal in thickness with a normal layering pattern. The pyloric outflow tract is patent. The small intestinal lumen is not dilated. The small intestinal wall thickness is normal with a normal layering pattern and appropriate mural detail. Discreet masses are not identified. The colonic wall is normal. There is no evidence of an obstructive pattern.

Pancreas

The region of the pancreas is isoechoic relative to surrounding omental fat. No obvious parenchymal abnormalities are observed. There is no evidence of regional inflammation or effusion.

Free Abdomen

The mesentery in the cranial abdomen and cranial to the urinary bladder is hyperechoic. There is no obvious evidence of free fluid.

Lymph nodes

(See "Other" category).

Other

A 1.91 cm irregular echogenic tissue structure with a questionable cystic area is observed at the cranial aspect of the bladder. It may be arising from or adjacent to, +/- arising from the apical wall of the bladder. Surrounding mesentery is hyperechoic.

In the subcutaneous region of the mammary gland, a 2.43 cm area of aggregated, slightly heterogenous and mildly cavitated tissue is visualized.

ULTRASONOGRAPHIC FINDINGS

Primary Findings

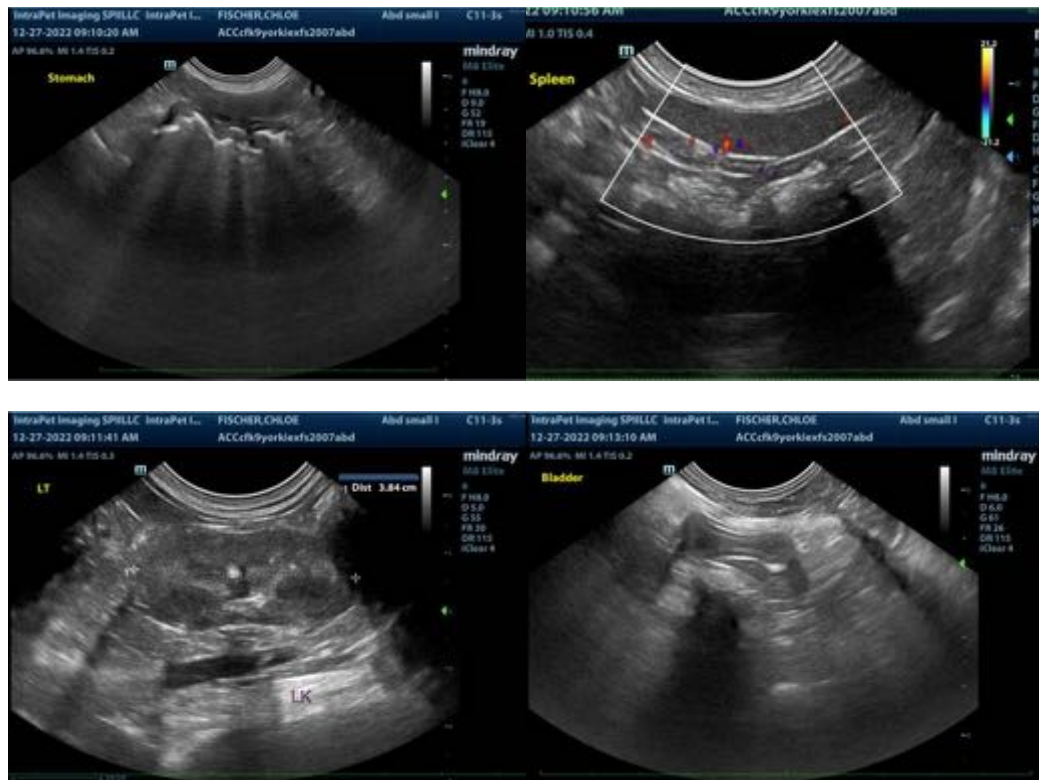
- The origin of the ill-defined tissue adjacent to the apex of the urinary bladder is unclear. It may be arising from urinary bladder wall, lymph node, mesentery, uterine stump, other. Differentials include granuloma, abscess, tumor, other. It is unclear whether this lesion is resulting in the persistent hematuria, or if a concurrent process (i.e., urinary tract infection) is present. Adjacent peritonitis is present.
- Irregular subcutaneous mammary tissue. Differentials include neoplasia, inflammatory tissue, other.

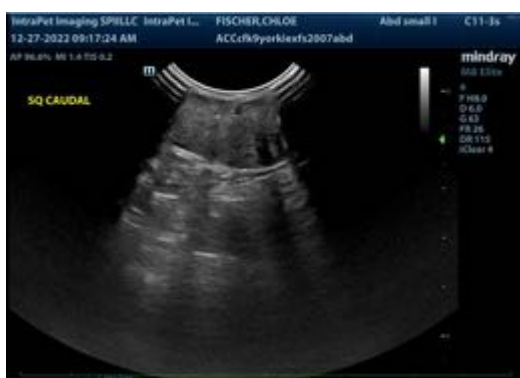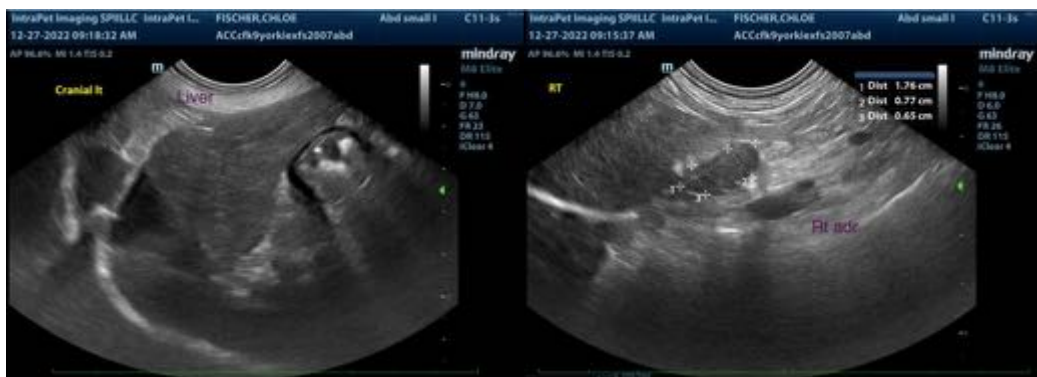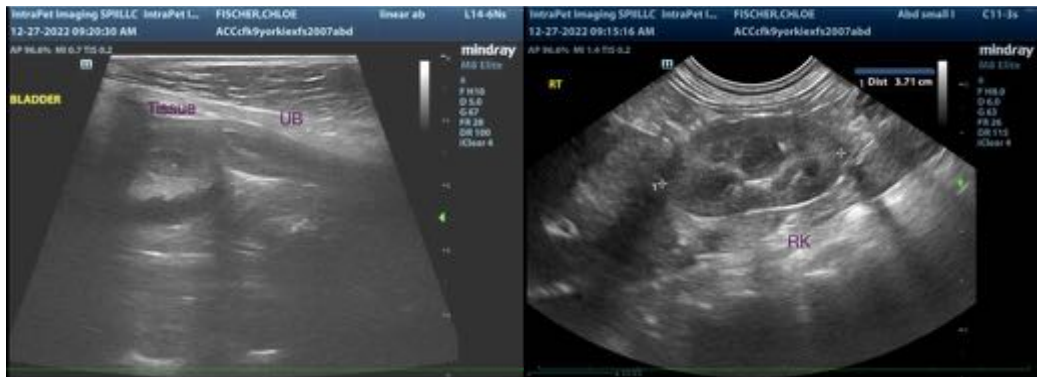
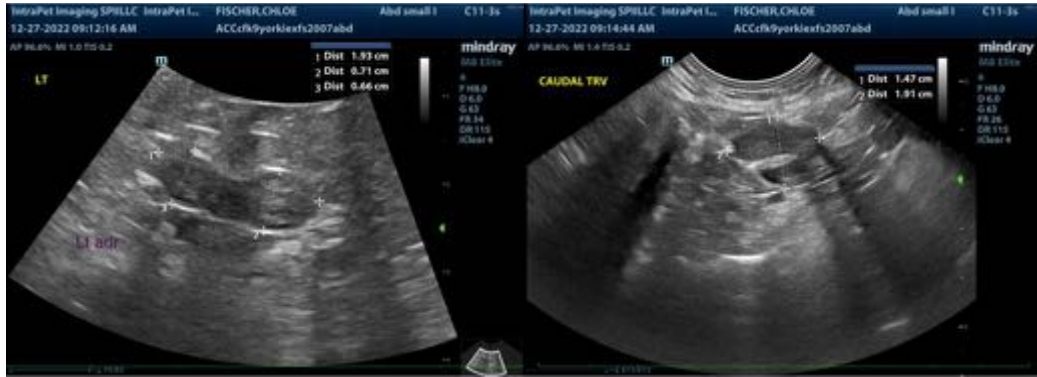Secondary Findings

- Bilateral chronic age-related renal changes with dystrophic mineralization and a left cortical cyst.
- The bilateral adrenomegaly is most consistent with hyperplastic change with a lower possibility of emerging tumors.
- Nonspecific diffuse hepatopathy. Differentials include in regenerative nodular hyperplasia, vacuolar hepatopathy, age-related remodeling, inflammatory disease, hepatotoxicosis (i.e., copper), infiltrative neoplasia, other hepatopathy.
- Gall bladder debris/sludge – non-mucocele
- Cranial peritonitis, the cause of which is unclear

INTERPRETATION OF THE FINDINGS & FURTHER RECOMMENDATIONS

- Baseline lab-work including a CBC, chemistry panel, and T4 is recommended, if not already performed.
- Regarding the hematuria, consider the following:
 1. Urine culture and sensitivity
 2. Urine BRAF test to evaluate for lower urinary tract neoplasia
 3. Consider an abdominal CT scan to further characterize the lesion adjacent to the urinary bladder apex. Alternatively, an abdominal exploratory with removal of the abnormal tissue with submission for histopathology should be considered. If surgery is pursued, removal of the abnormal mammary tissue may also be warranted.
- Consider a fine needle aspirate of the irregular mammary tissue.
- Three-view thoracic radiographs are recommended to assess cardiopulmonary status, particularly if the patient is to undergo general anesthesia.





The information and recommendations provided are based on the images presented by the referring veterinarian/sonographer. No evaluation can be communicated regarding pathology that was not visible in the image/video clips provided.

Thank you for this referral. If the clinical or image interpretation does not parallel your findings or if I can be of any further assistance, please contact me.

Andrea Nicastro, MPH, DVM, Diplomate DACVIM (Small Animal Internal Medicine)
info@SonoPath.com